

Frequency of Late Complications After Two Staged Aivar Bracka (AB) Repair of Hypospadias

Habibullah Shah^{1*}, Uzair Ahmed Qazi², Huma Gul³ and Saadia Atta Khan⁴

¹Consultant Plastic Surgeon, Habib Burn Center, Hair Transplant and Plastic Surgery Clinic, Zia Medical Complex, University Road, Peshawar, KPK, Pakistan

²Associate Consultant, Department of Plastic Surgery, Maroof International Hospital, Islamabad, Pakistan

³Resident Dermatologist Hayatabad Medical Complex, Peshawar, KPK, Pakistan

⁴Resident Anesthesiologist Department of Anesthesia, Shifa International Hospital, Islamabad, Pakistan

*Corresponding author: Dr. Habibullah Shah MBBS, FCPS, Habib Burn Center, Hair Transplant and Plastic Surgery Clinic, Zia Medical Complex, University Road, Peshawar, KPK, Pakistan, Tel: 0092-334-8800339; E-mail: drhabibullahshah@gmail.com

Received date: 10 Sep 2015; Accepted date: 20 Nov 2015; Published date: 25 Nov 2015.

Citation: Shah H, Qazi UA, Gul H, Khan A (2015) Frequency of Late Complications After Two Staged Aivar Bracka (AB) Repair of Hypospadias. J Surg Open Access 1(2): doi <http://dx.doi.org/10.16966/2470-0991.110>

Copyright: © 2015 Shah H, et al. This is an open-access article distributed under the terms of the Creative Commons Attribution License, which permits unrestricted use, distribution, and reproduction in any medium, provided the original author and source are credited.

Abstract

Hypospadias is a congenital anomaly in which due to the incomplete fusion of urethral folds the meatus opens on the ventral surface of the penis. It is the most common congenital malformation of the urethra with the prevalence of 1 in 200-300 live male births. The late complications of two stage AB repair of hypospadias are Urethrocutaneous fistula formation, urethral strictures, meatal stenosis and persistent chordee which occur within 6 weeks after the 2nd stage of the procedure. The aim of the study is to determine the frequency of late complications of two staged AB repair. The rationale of the study is that if the late complications rate of two staged AB repair comes out significantly lower than other studies then it will help reconsider the existing guidelines of hypospadias surgery.

Material and methods

This study was conducted at Plastic and reconstructive unit Hayatabad Medical Complex Peshawar for the period of 24 months (from August 2011 to July 2013). The total sample size was 370 patients. More over this was a descriptive cross-sectional study in which non-probability consecutive sampling technique was used.

Results

In this study mean age was 3 years with standard deviation ± 1.24 . All the patients were male in which 28% patients had Urethrocutaneous fistula, 8% patients had urethral structure. Frequency of complications among 370 patients was analyzed as late complications n=104(28%) patients had Urethrocutaneous fistula, n=30(8%) patients had urethral stricture, n=44(12%) patients had meatal stenosis and n=19(5%) patients had persistent chordee.

Conclusion

The most common late complication is Urethrocutaneous fistula and it can be reduced by adding a water proofing layer over the urethroplasty, keeping the suture line of subsequent layers eccentric and meticulous tissue handling under loupe magnification.

Keywords: Hypospadias; Aivar Bracka; 2 staged hypospadias repair; Urethrocutaneous fistula

Introduction

Hypospadias is the common congenital anomaly of the penis with an incidence of about 1 in 300 male live births [1]. Great variations exist in the prevalence of hypospadias most likely because of differences in genetics, environment, geography and in part to the differences in data collection methods [2]. The dorsal aspect of the penis is most often normal in hypospadias. Three associated anomalies classically found in hypospadias are; an ectopic meatus, a ventral curvature of the penis (chordee), and a defect of the ventral prepuce [3]. This chordee is due to the differences in length of the ventral and the dorsal sides of the penis known as corporocavernosal disproportion [4]. The urethral meatus is positioned ectopically and lies somewhere proximal to the normal site at the tip of glans ventrally. At least 70% of hypospadias is either glandular or distal penile and rest are mid penile and more severe proximal type [5]. Histologically, the urethral plate consists of well-vascularized tissue with large endothelial sinuses lined around an abortive urethral spongiosum [6]. This leads to fibrosis and cicatrization of urethral plate and at times leads to chordee formation [7].

The most common associated anomalies are cryptorchidism (8% to

10%) and inguinal hernia (9% to 15%) [8,9]. The etiology of hypospadias remains unknown with environmental exposure in the form of endocrine disruptors, the most likely explanation for the worldwide increase in the last three decades [3,10]. Interferences in the androgen metabolism, for example, 5 α -reductase deficit, defects of the androgen receptor, or gene defects are possible etiological factors for hypospadias, that are only found in <5% of the patients [8,11]. In patients with cryptorchidism or ambiguous genitalia, karyotyping should be considered [12].

The sequential steps for the successful repair of hypospadias are orthoplasty, urethroplasty, meatoplasty, glanuloplasty and prepucioplasty [13]. More than 300 procedures described for hypospadias reconstruction are evidence to both surgical ingenuity and dissatisfaction with the resultant solutions [14]. Among the choice of procedures for distal hypospadias is plate preservation procedures, like incised plate urethroplasty (Snodgrass), glans approximation procedures and Mathieu flip-flap repair, whereas for proximal hypospadias is extended application of incised plate urethroplasty with (snodgraft) or without graft, various flaps and graft urethroplasties, like Aivar Bracka in one or two stages [15]. Amongst the various methods reconstructing the hypospadiac urethra,

the two stages Aivar Bracka repair, introduced in 1995, has gained steady popularity worldwide during the last two decades fulfilling all the goals of hypospadias repair [13,16]. It is now more frequently performed in patients with inadequate urethral plate associated with moderate to severe chordee [17]. In fact hypospadias surgery carries very high complication rate even in experienced hands [18]. Complication rate depends on the severity of the anomaly [19]. So far the commonest complication has been fistula formation [17]. Urethral stricture, scarring, Chordee and painful erection are other trades off from various surgical procedures [20].

The goals of hypospadias reconstruction is to create a straight penis that is adequate for sexual intercourse, to reposition the urethral meatus to the penile tip to allow the patient to void while standing, to create a neourethra of adequate and uniform caliber and an aesthetically acceptable penis with a slit like vertically located meatus [21,22]. Figure 1 shows a two staged bracka repair. a – d is the first stage and e – h is the second stage (Figure 1).

The purpose of this study is to determine our rate of late complications with this technique. Efforts will be made to improve the surgical technique and to minimize late complications further, thereby reducing the number of subsequent surgeries.

Methods

This study was carried out in the Plastic and reconstructive unit of Hayatabad Medical Complex, Peshawar, Pakistan from August 2011 to July 2013.

A total number of 370 patients were included in the study. The inclusion criteria was set to include all male patients of any age group Presenting hypospadias associated with chordee along with narrow urethral plate and the exclusion criteria was set to exclude all previously operated cases or hypospadias cripples and coronal and glanular hypospadias without significant chordee along with wide urethral plate. Patients with ambiguous genitalia diagnosed by clinical examination with the findings of genitalia which could not be assigned to either sex were also excluded from the study.

All male patients with hypospadias (diagnosed by clinical findings of meatal opening on the ventral surface of the penis) fulfilling the inclusion

criteria was enrolled from Out-patients' department and referral from other departments. An informed consent was taken from all the patients after explaining the study protocol. After detailed clinical history and physical examination, all the hypospadias patients were subjected to two staged AB repair by plastic and reconstructive surgeons (with at least 5 years post-fellowship experience in hypospadias repair). In the first stage chordee (abnormal ventral curvature due to fibrosis) was released with sharp dissection and the wound was covered with inner preputial full thickness skin graft to provide the deficient urethral plate. The 2nd stage was performed after 6 months in which the grafted area of the penis was tabularized over a silicon urinary catheter with Polygalactone 6-0 suture. The catheter was removed on 7th post-operative day.

All the patients was observed for late complication in the corresponding follow-up visits on every week in the first month, and then every 3rd week till the end of 6th post operation month operative month to detect any late complications like Urethrocutaneous fistula, meatal stenosis, urethral strictures, persistent chordee.

The exclusion criteria had strictly followed to exclude confounders and bias in the results.

Results

This study was conducted at plastic and reconstructive unit Hayatabad Medical Complex, Peshawar in which a total of 370 patients were observed to find the frequency of common complication after two stage AB repair of hypospadias surgery and the results were analyzed as :

Age distribution among the patients was analyzed as most of the patients n=296(80%) were in age range 3-7 years followed by n=67(18%) patients were in age range 8-15 years and n=7(2%) patients were in age range 15-20 years. Mean age was 3 years with standard deviation ± 1.24 (Table 1).

Duration of surgery of in our patients was analyzed as n=340(92%) patients were operated in less than 60 minutes while n=30(8%) patients operated in more than 60 minutes. Mean duration of surgery was 30minutes with standard deviation ± 2.41 (Table 2).

Frequency of complications among 370 patients was analyzed as late complications n=104(28%) patients had Urethrocutaneous, n=30(8%) patients had urethral stricture, n=44(12%) patients had meatal stenosis and n=19(5%) patients had Persistent chordee (Table 3).

Association of complications with age distribution was analyzed as in 130 cases of edema, 109 patients were in age range 3-7 years, 18 patients were in age range 8-15 years and 3 patients were in age range 15-20 years. In 104 cases of Urethrocutaneous, 88 patients were in age range 3-7 years, 14 patients were in age range 8-15 years and 2 patients were in age range 15-20 years. In 30 cases of urethral stricture, 26 patients were in age range

AGE DISTRIBUTION	FREQUENCY	PERCENTAGE
3-7 year	296	80%
8-15 year	67	18%
15-20 year	7	2%
Total	370	100%

Table 1: Age Distribution (n=370)

Duration of Surgery	FREQUENCY	PERCENTAGE
< 1 hour	340	92%
> 1 hour	30	8%
Total	370	100%

Table 2: Duration of Surgery (n=370)

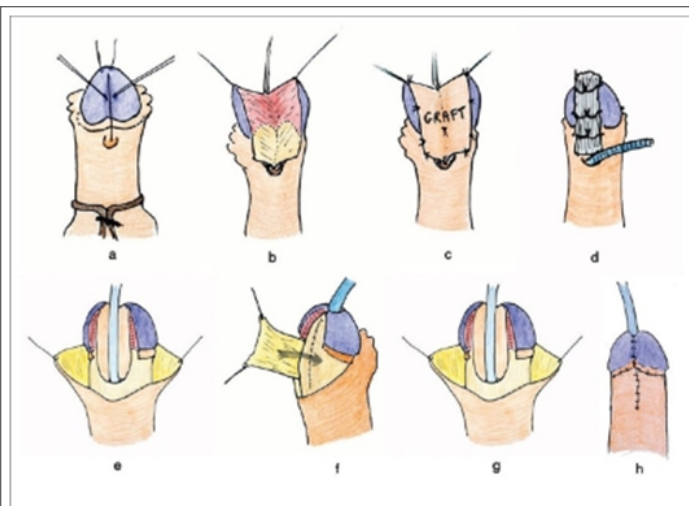


Figure1: (a,b,c,d) Stage 1 Aivar Bracka Repair
a: stay sutures and incision on the urethral plate
b: dissection of the urethral plate and release of chordee
c: Full thickness graft being secured
d: graft secured with tie over dressing
e: second stage, degloving of penile shaft
f: urethroplasty and water proofing layer being elevated
g & h: completed stage 2.

3-7 years and 4 patients were in age range 8-15 years. In 44 cases of meatal stenosis, 39 patients were in age range 3-7 years, 5 patients were in age range 8-15 years. In 19 cases of persistent chordee, 18 patients were in age range 3-7 years, 2 patients were in age range 8-15 years (Table 4).

Association of complications with duration of surgery was analyzed as in 104 cases of Urethrocutaneous fistula, 97 patients were operated in < 1 hour and 7 patients were operated in > 1 hours. In 30 cases of urethral stricture, 29 patients were operated in < 1 hour and 1 patient was operated in > 1 hours. In 44 cases of meatal stenosis, 42 patients were operated in < 1 hour and 2 patients were operated in > 1 hours. In 19 cases of persistent chordee all the 19 patients were operated in < 1 hour (Table 5).

Discussion

The AivarBracka (two stage) repair is a simple technical innovation that has revolutionized hypospadias surgery. In 2000, Rick wood et al. [23] published his result of 367 cases. He advocates a modern two stage terminalising repair that could produce an even caliber hairless neo-urethra with a vertically slit meatus and glans configuration. Not only did the result proved to be more sophisticated than with the available single stage methods, but also the surgery was relatively straightforward, reliable and reproducible [23].

The majority of clinicians across KPK, Pakistan, use the AivarBracka two stage repair (88%), Snodgrass (43%) or MAGPI (43%) [24]. Aslam et al. [24] in a 10-year review, highlight the advantages of the Bracka two stage repair in treating broad spectrum of pathologies with good outcome. They highlight the advantages of a normal looking slit like meatus (unlike MAGPI), ability to deal with chordee, scarless ventral surface and its universal application (unlike Snodgrass), and hence requiring surgeons to master only one technique [24].

There are several reasons for the great popularity of this technique, including its technical simplicity, and its great versatility and excellent

cosmetic results. Furthermore, being uniquely versatile it could be used as a universal repair for almost all types of hypospadias deformity. For a resident plastic surgeon dealing with a still modest number of hypospadias patients, being able to master one straight forward principle of repair and produce refined results in a broad spectrum of primary and re-operative problems is undoubtedly appealing [19].

In fact, hypospadias surgery carries very high complication rate even in experienced hands [19]. Complication rate depends on the severity of the anomaly. Our study shows that the incidence of hypospadias was found more in age range 3-7 years as 80% patients were found in the same age group. Secondly, most of the patients (92%) were operated in less than 60 minutes. Similar results were found in study done by Aslam et al. [17] in which most of the patients (90%) was in the age range 3-9 years.

Our study shows that the most occurring complication was Urethrocutaneous fistula which was found in 28% patients followed by meatal stenosis which was found in 12% patients, urethral stricture was found in 8% patients, Persistent chordee was found in 5% patients. Similar results were quoted by another study done by Aslam et al. [17] in which Urethrocutaneous was the leading risk factor found in 33% patients, meatal stenosis was found in 10% patients, urethral stricture was found in 7% patients, Persistent chordee was found in 3% patients.

Complications are common after hypospadias repair, ranging from fistulae to complete loss of the neo-urethra requiring total reconstruction [20]. Even in experienced hands, hypospadias repairs associated with the development of Urethrocutaneous fistulae. The Snodgrass technique is a simple technical innovation that has revolutionized hypospadias surgery. There are several reasons for this great popularity, including its technical simplicity, and its great versatility and excellent cosmetic results. Rick Wood et al. [23] in 1991 and reported the results of treatment of 367 patients with distal hypospadias, in whom an overall complication rate of 7% was found.

In the current study the mean age was 3 years with SD+1.24 which is comparable with 4.21} 4.4 years shown by Tabassi et al. [25] in their study from Iran and contrary to 22.72} 7.75 months by Al-Saied et al. [26] in their study from Saudi Arabia.

The location of the hypospadias in our study (48.5% had distal penile hypospadias while 24.2% had coronal hypospadias) is similar to the results reported by Tabassi et al. [25] (distal penile in 59% cases). The main complication of hypospadias repair in this series is Urethrocutaneous fistula which is found in 28% cases. Dodson et al. [27] reported fistula rate of 50% in their study which higher than the current study. Braga et al. [28] reported fistula formation rate of 14% which is lower than our study. Fistula formation has multifactorial etiology i.e. surgical technique, delicate tissue handling, patients, age, type of hypospadias defect, surgeon experience, waterproof urethroplasty coverage, and concomitant foreskin reconstruction. In our study the fistula rate was slightly higher because of the learning curve.

The meatal abnormality was noted in 12% cases in this series which comparable with 10.34% reported by Tabassi et al. [25] Other studies have shown frequency of meatal abnormalities (stenosis) from 6-20%.

In our study the fistula rate was found significantly lower when performed in age group above 5 years which may be due to the adequate phallus size. The late complications frequencies were found higher when the operation time was higher than 60 min.

TIPS (Snodgrass) and snodgraft procedure employ the preservation of urethral plate as an important part of the neo-urethra formation with favorable outcomes [15]. However, it has the inherited problem of limited application and is applied in some coronal and distal hypospadias

COMPLICATIONS	FREQUENCY	PERCENTAGE
Urethrocutaneous Fistula	104	28%
Urethral stricture	30	8%
Meatal stenosis	44	12%
Presistant chordee	19	5%

Table 3: Complications (n=370)

COMPLICATIONS VS AGE	3-7 years	8-15 years	15-20 years	Total
Urethrocutaneous Fistula	88	14	2	104
Urethral stricture	26	4		30
Meatal stenosis	39	5		44
Presistant chordee	18	2		19

Table 4: Association of Complications in Age Group (n=370)

COMPLICATIONS VS AGE	< 1 hour	> 1 hour	Total
Urethrocutaneous Fistula	97	7	104
Urethral stricture	29	1	30
Meatal stenosis	42	2	44
Presistant chordee	19		19

Table 5: Association of Complications in Duration of Surgery (n=370)

with mild to moderate chordee [20]. Also the problems of fish mouth appearance and stenosis of urinary meatus make the repair less favorable [20]. A technique to repair hypospadias with universal applicability in most variants would be appealing.

Conclusion

The current study conclude that post-operative Urethrocutaneous fistula is the main complication of hypospadias repair, its rate is significantly lower in age group above 5 years and the complication frequency increases when the operation time is less than 60 min. Snodgrass repair has acceptable complications rates in the hypospadias repair. Further multi-centre studies are suggested to confirm the results in our setup.

References

1. Hayashi Y, Kojima Y (2008) Current concepts in hypospadias surgery. *Int J Urol*; 15: 651-64.
2. Gallentine ML, Morey AF, Thompson IM (2001) Hypospadias: a contemporary epidemiologic assessment. *Urology*; 57: 788-90.
3. Baskin LS, Ebber MB (2006) Hypospadias: anatomy, etiology and technique. *J Pediatric Surg*; 41: 463-72.
4. Leung AK, Robson WL. (2007) Hypospadias: an update. *Asian J Androl*; 9: 16-22.
5. Bath AS, Bhandari PS, Mukherjee MK (2003) Repair of distal Hypospadias by the tabularized incised plate Urethroplasty: A simple versatile technique. *Indian J Plast Surg* ; 36: 23-5.
6. Erol A, Baskin LS, Li YW, Liu WH (2000) Anatomical studies of the urethral plate: why preservation of the urethral plate is important in hypospadias repair. *BJU International*; 85: 728-734.
7. Catti M, Demede D, Valmale AF, Mure PY, Hameury F, et al.(2008) Management of severe hypospadias. *Indian J Urol* ; 24: 233-40.
8. Khuri FJ, Hardy BE, Churchill BM (1981) Urologic anomalies associated with hypospadias. *UrolClin North Am*; 8: 565-71.
9. Wang MH, Baskin LS (2008) Endocrine Disruptors, Genital Development, and Hypospadias. *J Androl*; 29: 499-5.
10. Hinman FJ (1993) Penis and Male Urethra. *Atlas of Urosurgical Anatomy*. Philadelphia, Pa: WB Saunders: 417-70.
11. Belman AB (1997) Hypospadias update. *Urology*; 49: 166-72.
12. Keating MA, Duckett JW (1998) *Hypospadiology: Hand book of genito-urinary surgery vol1*. 2nd ed. Blackwill Science Ltd ; 319-36.
13. Bracka A (2008) Role of two-stage repair in modern hypospadiology. *Indian J Urol*; 24: 210-218.
14. Aslam M, Obaidullah, Majid A (2006) Two stage AivarBracka repair in hypospadias salvage cases. *J Postgraduate Med Institute*; 20: 203-6.
15. Bracka A (1995) Hypospadias repair: The two-stage alternative. *Br J Urol*; 76: 31-41.
16. Haxhirexa KN, Castagnetti M, Rigamonti W, Manzoni GA (2008) Two-stage repair in hypospadias. *Indian J Urol* ; 24: 226-32.
17. Aslam M, Obaidullah, Mumtaz N (2005) Outcome of Urethra Cutaneous fistula repair after Hypospadias. *Pakistan J Med Res*; 44: 23-6.
18. Bhat A, Mandal AK (2008) Acute postoperative complications of hypospadias repair. *Indian J Urol* ; 24 : 241-8.
19. Chrzan R, Dik P, Klijin AJ, De-jong TP (2007) Quality assessment of Hypospadias repair with emphasis on techniques used and experience of pediatric urologic surgeons. *Urology*; 70: 148-52.
20. Djordjetic ML, PerovicSV, Salvkovic Z, Djakovic N (2006) Longitudinal dorsal dartos flap for prevention of fistula after a Snodgrass Hypospadias procedure. *EurUrol*; 50: 53-57.
21. Snodgrass WT (2005) Snodgrass technique for hypospadias repair. *BJU Int*; 95: 683-93.
22. Soomro NA, Neal DE (1998) Treatment of hypospadias: an update of current practice. *Hosp Med*; 59: 553-6.
23. Rickwood AM, Anderson PA (1991) One-stage hypospadias repair:experience of 367 cases. *Br J Urol* ; 67: 424-28.
24. Obaidullah, Aslam M (2005) Ten year review of Hypospadias surgery from a single center. *BJPS*; 58: 780-89.
25. Tabassi KT, Mohammadi S (2010) Tunica Vaginalis Flap as a Second Layer for Tubularized Incised Plate Urethroplasty. *Urol J*; 7: 254-7.
26. Al-Saied G, Gamal A (2009) Versatility of tubularized incised plate urethroplasty in the management of diff erent types of hypospadias: 5-year experience. *Afr J PaediatrSurg*; 6: 88-92.
27. Dodson JL, Baird AD, Baker LA, Docimo SG, Mathews RI (2007) Outcomes of delayed hypospadias repair: implications for decision making. *J Urol*; 178: 278-81.
28. Braga LHP, Lorenzo AJ, Salle JLP (2008) Tubularized incised plate urethroplasty for distal hypospadias: A literature review. *Indian J Urol*; 24: 219-25.