

Revascularization of Atherosclerotic Renal Artery Stenosis in Selected Patients: Benefits on Kidney and Cardiac Function

Rigas G Kalaitzidis¹, Alexandra Myari¹, Olga Balafa¹, Sofia Xiromeriti¹, Dimitrios Stagikas¹, Lampros K Michalis², Christos Katsuras² and Moses S Elisaf^{1,3,*}

¹Department of Nephrology, University Hospital of Ioannina, Greece, University Hospital of Ioannina, Ioannina, Greece

²Department of Cardiology, Medical School, University of Ioannina, Ioannina, Greece

³Department of Internal Medicine, Medical School, University of Ioannina, Ioannina, Greece

*Corresponding author: Moses S Elisaf, MD, FASA, FRSH, Professor of Medicine, Department of Internal Medicine, Medical School, University of Ioannina, Greece, Tel: +302651007509;

E-mail: egepi@cc.uoi.gr

Received date: 11 Nov 2016; Accepted date: 16 Jan 2017; Published date: 20 Jan 2017.

Citation: Kalaitzidis RG, Myari A, Balafa O, Xiromeriti S, Dimitrios S, et al. (2017) Revascularization of Atherosclerotic Renal Artery Stenosis in Selected Patients: Benefits on Kidney and Cardiac Function. *Int J Nephrol Kidney Failure* 3(1): doi <http://dx.doi.org/10.16966/2380-5498.139>

Copyright: © 2016 Kalaitzidis RG. This is an open-access article distributed under the terms of the Creative Commons Attribution License, which permits unrestricted use, distribution, and reproduction in any medium, provided the original author and source are credited.

Abstract

The atherosclerotic renal artery stenosis is mostly diagnosed in the elderly and often coexists with other vascular diseases. It is a progressive disease that can lead to resistant hypertension and progressive loss of functional renal mass. Additionally, it has been associated with ischemic heart disease and increased cardiovascular morbidity and mortality.

The treatment of atherosclerotic renal artery stenosis in patients with hypertension and/or renal function remains a dilemma. The clinical improvement of a possible intraluminal stent placement in atherosclerotic lesions is unpredictable. Likewise, clinical evidence that supports an intervention in case of atherosclerotic renal artery stenosis and resistant hypertension is controversial. Clinical indication for revascularization include an acute deterioration of renal function that is a >30% decrease in estimated glomerular filtration rate (eGFR) over ≤ 3 months in patients with a previously stable or a slowly progressive renal disease with no evidence of glomerular disease. A significant restoration of kidney and cardiac function after a revascularization procedure may occur. This fact underlies the interdependence between the two systems, the kidney and the heart.

In this article we describe a rare case of atherosclerotic renal artery stenosis in a patient with heart failure and review the recent literature regarding this entity.

Keywords: Atherosclerotic renal artery stenosis; Progressive renal disease; Resistant hypertension; Revascularization

Case Report

A 75 years old man with known congestive heart failure was admitted to the hospital due to significant renal insufficiency to be prepared for initiation of dialysis with the method of peritoneal dialysis.

Past medical history included hypertension of 10 years duration. Two years ago he suffered from an acute myocardial infarction, and underwent an aorto-coronary bypass of 3 vessels, and a mechanical mitral valve replacement. Furthermore, the patient had also dyslipidemia, benign prostatic hypertrophy and he was receiving low doses of corticosteroids for rheumatic polymyalgia.

The patient visited for the first time our outpatient hypertension clinic in 2006 with impaired renal function [(serum creatinine 1.5 mg/dL and estimated glomerular filtration rate (eGFR) 44.9 mL/min/1.73m² CKD-EPI (Chronic Kidney Disease Epidemiology Collaboration) equation], which was noticed after the initiation of candesartan 16 mg o.d due to increased blood pressure levels. Renin angiotensin aldosterone system (RAAS) blocker was discontinued and an ultrasound examination of kidneys was performed, which revealed dimensions 11.3 cm for the left kidney and 9.8 cm for the right kidney with a satisfactory cortical-medullary differentiation, while the color ultrasonography of renal arteries revealed a stenosis on the right renal artery <50%. A modification of the antihypertensive treatment was performed and clear recommendations for avoiding RAAS inhibitors were given (Table 1).

The next two years the patient was regularly followed in the outpatient hypertension clinic, with gradual addition of antihypertensive agents, including amlodipine 10 mg o.d., carvedilol 12.5 mg b.d., indapamide 1.5 mg o.d., moxonidine 0.3 mg o.d. and atorvastatin 20 mg o.d. for dyslipidemia. Renal function was in a stage 2 CKD (serum creatinine 1.1 mg/dL and eGFR 66.2 mL/min/1.73m² CKD-EPI). Since then he stopped monitoring in our clinic and visited a private physician.

Two years before his admission, he was admitted to another hospital due to an acute myocardial infarction. A diagnosis of coronary heart disease was made and an aorto-coronary bypass was performed, and due to mitral valve regurgitation a replacement of the mitral valve with a mechanical valve was also performed. He was discharged with mild renal insufficiency (serum creatinine 1.4 mg/dL, eGFR –CKD EPI 49.5 mL/min/1.73 m²) and the recommendation for a close monitoring by a cardiologist and nephrologist. The pharmaceutical treatment included: lisinopril 10 mg o.d., amlodipine 10mg o.d., spironolactone 25 mg o.d., tamsulosin 0.4 mg o.d., bisoprolol 5 mg o.d., furosemide 20 mg b.d. as well as acenocoumarol, atorvastatin 20 mg o.d. and small doses of methylprednisolone 4 mg o.d. In the last month before the referral, serum creatinine was 3.8 mg/dL, corresponding to eGFR CKD EPI 14.6 ml/min/1.73².

Clinical examination

Patient weighing 65 Kg, 1,67 m height with a body mass index (BMI) 23,3 Kg/m². Blood pressure measurements were 190/80 mmHg in supine position and 172/80 mmHg in seating position, with similar measurements

	2 years before the admission to hospital	Admission to hospital	Stent placement	1 week after	1 month after	2 months after	6 months after	12 months after	24 months after
Urea (mg/dl)	36	217	249	127	37	41	32	30	32
Creatinine (mg/dl)	1.4	3.8	4.8	2.2	1.2	1.6	1.5	1.3	1.3
GFR MDRD (ml/min/1.73 m ²)	52.8	16.5	12.7	31.2	62.7	45.0	48.5	57.0	56.9
GFR CKD-EPI (ml/min/1.73 m ²)	49.5	14.6	11.0	28.2	58.8	41.5	44.9	53.0	52.6
Hb (g/dl)	13.9	10.9	10.3	11.3	13	14	13.2	13.4	13.3
Ht%	42.8	32.9	31.1	34.9	39.2	45	41	40	41

Table 1: Laboratory tests before and after revascularization of the left renal artery: GFR MDRD: glomerular filtration rate- Modification of Diet in Renal Disease equation; GFR CKD-EPI: glomerular filtration rate- Chronic Kidney Disease Epidemiology Collaboration equation

at both arms, while the pulse ranged between 72-76/min. A blowing in the right carotid and the two femoral arteries was found. The ECG had sinus rhythm with left bundle branch block and negative T waves in leads I, a VL and V6.

An ultrasound of the heart showed left ventricular hypertrophy, mild thickening of the interventricular septum (IVSd=0.95), with severely impaired functionality contractility, decreased ejection fraction (20-25.9%), as well as immobility and hypokinesia of the lower anterior wall.

Further investigations

Laboratory test revealed : glucose 117 mg/dl, urea 249 mg /dl, creatinine 4,8 mg / dl, sodium 127 mmol / L, potassium 4,6 mmol / L, hematocrit, 31.1%, hemoglobin 10,3 g / dl, leukocytes 5,640 / L, platelets 246,000 / L, international normalized ratio(INR) 3,17, total-cholesterol 210 mg / dl, triglycerides 190 mg / dl, HDL-cholesterol 38 mg / dl, LDL-cholesterol 134 mg / dl, while HbA1c level was 5.6%.

Renal ultrasonography showed that the right kidney was small and textured, while the left had sufficient size, with an adequate cortical-medullary differentiation despite the significant renal dysfunction.

Renal scintigraphy confirmed the original image and revealed a non-functional, textured right kidney with dimensions 6.3cm × 3.2 cm and a left kidney with dimensions 11.5 cm × 4.2 cm.

Patient's problems

Male 75 years old with uncontrolled hypertension, coronary artery disease, mechanical mitral valve, heart failure, dyslipidemia, prostatic hypertrophy and impaired renal function.

Possible diagnosis

Atherosclerotic renal artery stenosis, cardiorenal syndrome, hypertensive nephrosclerosis.

Final diagnosis

Impaired renal function, likely due to undiagnosed atherosclerotic renal artery stenosis in one functioned kidney, which was further, aggravated by the use of RAAS inhibitors.

Treatment

The patient underwent a conventional angiography in renal arteries. The examination found a marked narrowing of the range of 99% in left renal artery (figure 1). The right kidney was not depicted. Then, he underwent percutaneous revascularization by placing intraluminal stent in the left renal artery. After the therapeutic intervention a gradual kidney function improvement was noticed (figure 2) which was followed by a gradual improvement of the cardiac function (Figure 3).

In his latest appointment, two years after revascularization of the left renal artery, renal function remained stable (serum creatinine 1.3 mg/

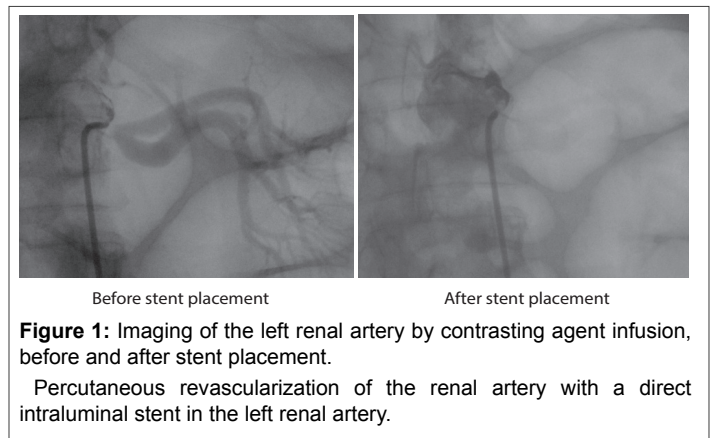


Figure 1: Imaging of the left renal artery by contrasting agent infusion, before and after stent placement.

Percutaneous revascularization of the renal artery with a direct intraluminal stent in the left renal artery.

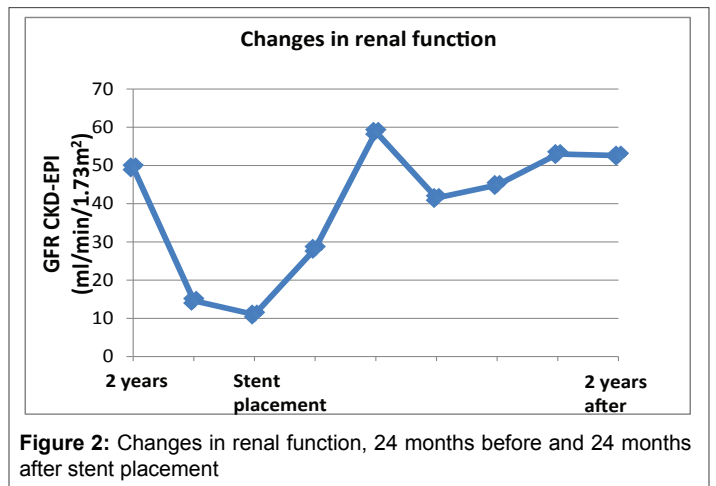


Figure 2: Changes in renal function, 24 months before and 24 months after stent placement

dl, with eGFR EPI 65 ml/min /1.73²) while cardiac function improved significantly (Table 2). Two years after revascularization blood pressure was well controlled. The antihypertensive treatment included: lisinopril 10 mg o.d., amlodipine 5 mg o.d., spironolactone 25 mg o.d., bisoprolol 5 mg o.d., and furosemide 20 mg b.d. Thus the improvement of renal function was due to the revascularization procedure and not any change in antihypertensive therapy.

Discussion

The atherosclerotic renal artery stenosis represents > 90% of cases of renal artery stenosis [1]. In most cases hypertension and renal dysfunction coexist. The disease is mostly diagnosed in the elderly and often coexist with other vascular diseases [1]. The incidence of the disease, due to non-specific symptoms is difficult to calculate. However, data shows that

	2 years before admission	Admission to hospital	Stent placement	4 months After	6 months after	9 months after	12 months after	18 months after	24 months after
Echo EF%	65	25.5		25.6	33	36	51	52	51
LVEDD	59	60		60	64	62	46	59	60
IVSD	12	11		11	10	10	16	14	14
PWD	12	10		10	10	11	9	14	13

Table 2: Cardiac function before and after revascularization of the left renal artery: Echo EF: ejection fraction; LVEDD: left ventricular and diastolic diameter; IVSD: intra-ventricular septal thickness; PWD: left ventricular posterior wall thickness

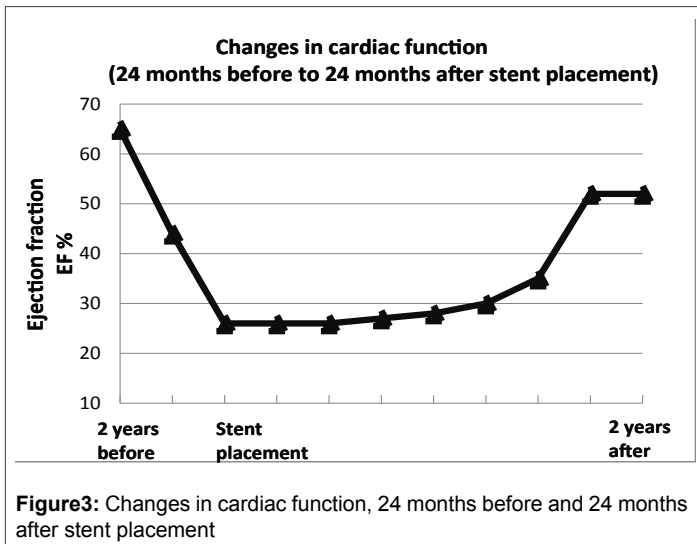


Figure 3: Changes in cardiac function, 24 months before and 24 months after stent placement

occurs in about 6.5% of elderly patients [2]. The disease is associated with increasing age, low levels of high density lipoproteins cholesterol and uncontrolled systolic blood pressure [2].

The atherosclerotic renal artery stenosis is a progressive disease that can lead to resistant hypertension and progressive loss of functional renal mass resulting in chronic kidney disease [3]. This particular patient experienced progressive deterioration of renal function. The progressive atherosclerotic occlusion of the right kidney was not diagnosed promptly. Probably the compensatory hyperactivity of the left kidney did not allow the recognition of the problem. However, the gradual development of stenosis on the left renal artery led to the deterioration of the patient's renal function and highlighted the magnitude of the problem.

The presence of atherosclerotic renal artery stenosis has been associated with ischemic heart disease and increased cardiovascular morbidity and mortality [3]. Possibly, in our case the progression of coronary heart disease who led to the occurrence of acute myocardial infarction and the simultaneous replacement of the mitral valve may be attributed at least in part to the atherosclerotic renal artery stenosis.

The treatment of atherosclerotic renal artery stenosis in patients with hypertension and / or renal function remains a dilemma. A point of importance is that the clinical improvement after intraluminal stent placement in atherosclerotic lesions is unpredictable. Furthermore, the clinical evidence that supports an intervention in cases of atherosclerotic renal artery stenosis and resistant hypertension is controversial.

Of note, there are multiple factors other than the decrease in renal blood flow, which can contribute to the damage of renal tissue. For example, there is now increasing evidence for the presence of an inflammatory process in the post-stenotic area of renal parenchyma, which gradually leads to endothelial damage in kidney tissue and increase the production of free radicals and oxidative stress [4, 5].

A significant narrowing of the lumen in the range of 70-80% is crucial to induce a reduction in renal perfusion [6]. In this case, a subsequent activation of the RAAS system will occur leading to increased plasma renin activity levels which is the main indicator of renovascular hypertension existence [7]. Several lines of evidence support that just the presence of an anatomical damage is not automatically translated into the presence of a significant hemodynamic disturbance. Furthermore, it is well known that a certain degree of stenosis should not exert the same hemodynamic effect in different patients. Currently, the best way to assess the hemodynamic impact of the stenosis is ultra sonography, done by an experience radiologist. However, most of hypertension clinics never assessed stenosis with this kind of tool, and this maybe one of the reasons that prospective trials for patients with ARAS such as Cardiovascular Outcomes for Renal Artery Lesions (CORAL) [8] trial and Angioplasty and Stenting for Renal Atherosclerotic Lesions (ASTRAL) [9] trial fail to recover renal function and to exhibit a benefit beyond that achieved with current medical therapy [10].

Percutaneous revascularization may be considered for treatment of an bilateral or solitary viable kidney with a hemodynamically significant stenosis as well as in cases of an accelerated hypertension, resistant hypertension, malignant hypertension, hypertension with an unexplained unilateral small kidney [11]. Of note, the therapeutic intervention with an intraluminal stent placement may be considered in the presence of uncontrolled blood pressure while using medications, a situation which in most cases is followed by a significant and rapid deterioration in kidney function [11].

In the diagnosis of atherosclerotic renal artery stenosis a considerable number of difficulties should be taken into account. In this regard it is of interest that even current imaging methods are likely to overestimate the actual narrowing of the artery lumen. Thus, even the classic angiography, which is considered as the "gold standard" and one of the main criteria for the recruitment of patients in the clinical studies, is far from being optimal. Additionally, very often atheromatous atherosclerotic renal artery stenosis is a diffuse entity, with multiple areas of stenosis and post-stenotic dilatation and this phenomenon may affect the accuracy of the measurements.

In a retrospective study, including patients who experienced malignant hypertension and acute loss of kidney function, the medication used were compared to an invasive revascularization. With revascularization procedures, a significant reduction in the risk for death [hazard ratio (HR) 0, 12 (95% confidence interval (CI) 0, 02 - 0, 77), P=0.01] as well as for cardiovascular events [HR 0, 28 (95% CI 0, 10 - 0, 60), P<0,001] was noticed [12]. Indeed, patients who simultaneously experience rapid deterioration of renal function and uncontrolled hypertension were ultimately these who can benefit from renal revascularization [12]. Thus, the clinical indications for revascularization procedure could include an acute deterioration of renal function >30% decrease in eGFR over ≤ 3 months in patients with a previously stable or a slowly progressive renal disease with no evidence of glomerular disease [13]. This specific group

of patients is by far already sensitive to small changes in perfusion since the atherosclerotic renal artery stenosis has evolved sufficiently to cause severe hypoperfusion beyond the upper limit of the kidneys adaptive capacity [14].

Interestingly, case series have shown a significant restoration of kidney function after a revascularization procedure, occurred even in patients considered in the pre-end stage kidney failure and/or in dialysis [15].

Another point of interest after the procedure is the concomitant cardiac function improvement (Figure 3). It is well known that even moderate renal impairment is associated with increased cardiovascular morbidity and mortality [16]. These data have led to the recognition that chronic kidney disease is an independent risk factor for the development of cardiovascular disease. In fact, nowadays there is a growing awareness of the interdependence between these two systems, the kidney and the heart [17].

From a pathophysiological point of view the deterioration of glomerular filtration rate leads to activation of multiple compensatory mechanisms, including RAAS system stimulation, activation of the sympathetic nervous system as well as activation of calcium-parathyroid axis. These mechanisms can induce a progressive deterioration of both cardiac and renal function [17]. Thus, our case can be considered as a case of cardio-renal syndrome. The term cardio-renal syndrome was derived in an effort to indicate a bidirectional interaction between the heart and the kidney [18]. The chronic reno-cardiac syndrome (Type 4) is the subtype of the syndrome in which patients with renal dysfunction have also evidence of cardiac disease. The coexistence of cardiac and renal disease significantly increases mortality, morbidity, and cost of care [16]. On the other hand, in our case it is obvious that the transluminal renal revascularization results not only in the improvement of kidney function (figure 2), but also in the improvement of cardiac function (Figure 3). Thus, revascularization procedure can induce an improvement of kidney function followed by an improvement in the cardiac function.

Conclusion

Today the current challenge is to identify patients with atherosclerotic renal artery stenosis who are likely to benefit from the procedure of kidney revascularization. Current technological developments in imaging offer the opportunity to support this option. In case of revascularization procedures the clinician should be carefully weighing benefits and risks, taking into account the comorbidities of patients as well as the possibility of improving their lifestyle. An unexplained worsening or malignant hypertension with or without acute renal failure in patients with previously controlled blood pressure levels should raise the suspicion of severe acute renal ischemia. On the other hand in these cases an improvement of kidney function could be coupled with a simultaneous improvement of the cardiac function, as it was the case in our patient.

Consent

Written informed consent was obtained from the patient for publication of this Case report and any accompanying images.

Competing Interest

The Authors declare that there is no conflict of interest.

References

- Cheung CM, Hegarty J, Kalra PA (2005) Dilemmas in the management of renal artery stenosis. *Br Med Bull* 1: 35-55.
- Hansen KJ, Edwards MS, Craven TE, Cherr GS, Jackson SA, et al. (2002) Prevalence of renovascular disease in the elderly: a population-based study. *J Vasc Surg* 3: 443-451.
- Zanoli L, Rastelli S, Marcantoni C, Capodanno D, Blanco J, et al. (2014) Non-hemodynamically significant renal artery stenosis predicts cardiovascular events in persons with ischemic heart disease. *Am J Nephrol* 40: 468-477.
- Lerman LO, Textor SC, Grande JP (2009) Mechanisms of tissue injury in renal artery stenosis: ischemia and beyond. *Prog Cardiovasc Dis* 52: 196-203.
- Zhu XY, Chade AR, Rodriguez-Porcel M, Bentley MD, Ritman EL, et al. (2004) Cortical microvascular remodeling in the stenotic kidney: role of increased oxidative stress. *Arterioscler Thromb Vasc Biol* 24: 1854-1859.
- May AG, De Weese JA, Rob CG (1963) Hemodynamic effects of arterial stenosis. *Surgery* 53: 513-24.
- Vaughan ED Jr (2014) Curable renal hypertension: renin, marker or cause? Question answered. *Am J Hypertens* 27: 1000-1003.
- Herrmann SM, Saad A, Textor SC (2015) Management of atherosclerotic renovascular disease after Cardiovascular Outcomes in Renal Atherosclerotic Lesions (CORAL). *Nephrol Dial Transplant* 30: 366-375.
- Wheatley K, Ives N, Gray R, Kalra PA, Moss JG, et al. (2009) Revascularization versus medical therapy for renal-artery stenosis. *N Engl J Med* 361: 1953-1962.
- Textor SC, Lerman LO (2015) Paradigm Shifts in Atherosclerotic Renovascular Disease: Where Are We Now? *J Am Soc Nephrol* 26: 2074-2080.
- Hirsch AT, Haskal ZJ, Hertzner NR, Bakal CW, Creager MA, et al. (2006) ACC/AHA Guidelines for the Management of Patients with Peripheral Arterial Disease (lower extremity, renal, mesenteric, and abdominal aortic): a collaborative report from the American Associations for Vascular Surgery/Society for Vascular Surgery, Society for Cardiovascular Angiography and Interventions, Society for Vascular Medicine and Biology, Society of Interventional Radiology, and the ACC/AHA Task Force on Practice Guidelines (writing committee to develop guidelines for the management of patients with peripheral arterial disease)—summary of recommendations. *J Vasc Interv Radiol* 17: 1383-1397.
- Ritchie J, Green D, Chrysochou C, Chalmers N, Foley RN, et al. (2014) High-risk clinical presentations in atherosclerotic renovascular disease: prognosis and response to renal artery revascularization. *Am J Kidney Dis* 63: 186-197.
- Murray S, Martin M, Amoedo ML, Garcia C, Jornet AR, et al. (2002) Rapid decline in renal function reflects reversibility and predicts the outcome after angioplasty in renal artery stenosis. *Am J Kidney Dis* 39: 60-66.
- Textor SC, Novick AC, Tarazi RC, Klimas V, Vidt DG, et al. (1985) Critical perfusion pressure for renal function in patients with bilateral atherosclerotic renal vascular disease. *Ann Intern Med* 102: 308-314.
- Dwyer JP, Greco BA, Lewis JB (2009) Evaluation of renal artery stenosis in dialysis patients. *Semin Dial* 22: 519-523.
- Shastri S, Sarnak MJ (2010) Cardiovascular disease and CKD: core curriculum 2010. *Am J Kidney Dis* 56: 399-417.
- Tumlin JA, Costanzo MR, Chawla LS, Herzog CA, Kellum JA, et al. (2013) Cardiorenal syndrome type 4: insights on clinical presentation and pathophysiology from the eleventh consensus conference of the Acute Dialysis Quality Initiative (ADQI). *Contrib Nephrol* 182: 158-173.
- House AA (2012) Cardio-renal syndrome type 4: epidemiology, pathophysiology and treatment. *Semin Nephrol* 32: 40-48.